

Great Blue Heron

WTC # 14-234

Wildlife Rounds

9/8/14

Joyce Huang and Ashlee Boone

Case History

Found in Good Samaritan's front yard and brought to
Tugaloo Animal Hospital

Transported to UGA CVM



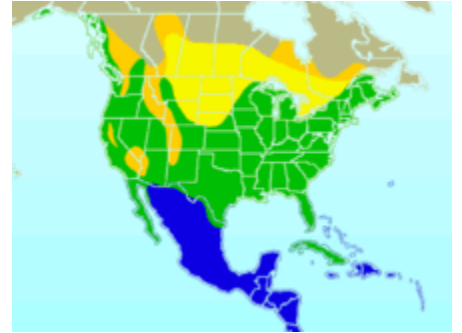
Blue Heron

Appearance: Largest of the North American herons (four feet tall); long legs, a sinuous neck, thick, daggerlike bill, blue-gray color, wide black stripe over the eye.

Habitat: Shores of North and Central America, the Caribbean, and the Galapagos Islands

Hunting: Wade slowly or stand statue-like, stalking fish and other prey in shallow water

Watch for the lightning-fast thrust of the neck and head as they stab fish with their strong bills.



Handling Blue Herons

When found injured in the wild:

Capture with a long-handled, large fishing net.

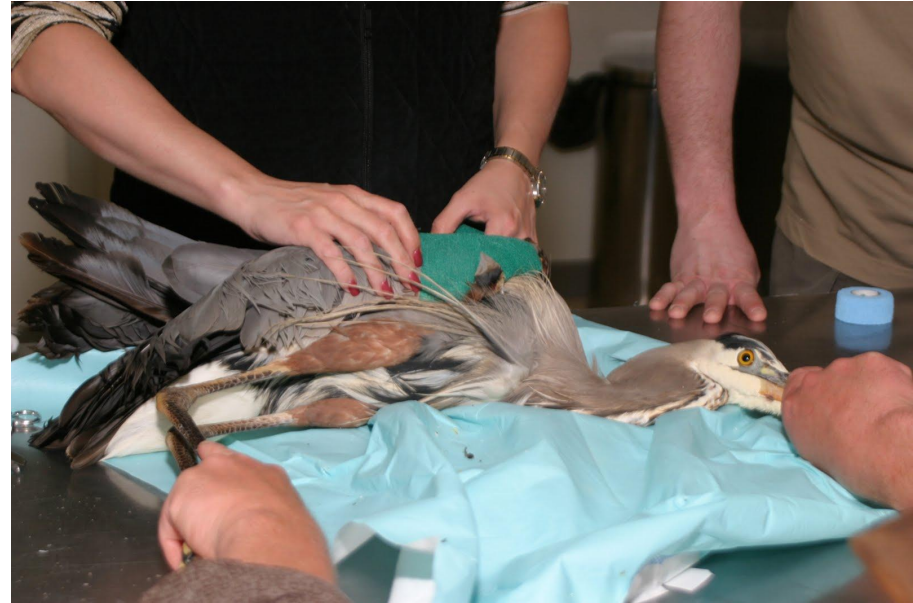If a net is not available, use a blanket or coat and

Cover the entire bird before picking it up.

If you must carry the bird in your arms, be sure to keep its beak away from your face.

When handling for a physical exam, two things to avoid:

The talons and the beak



Physical Exam

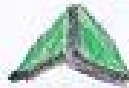Temperature: N/A

Heart Rate: 204 bpm

Respiratory Rate: labored

Weight: 1.86 kg

BCS: 1/5



Physical Exam Cont.

QAR

Fractures (explained in the next slide)

Bite wounds

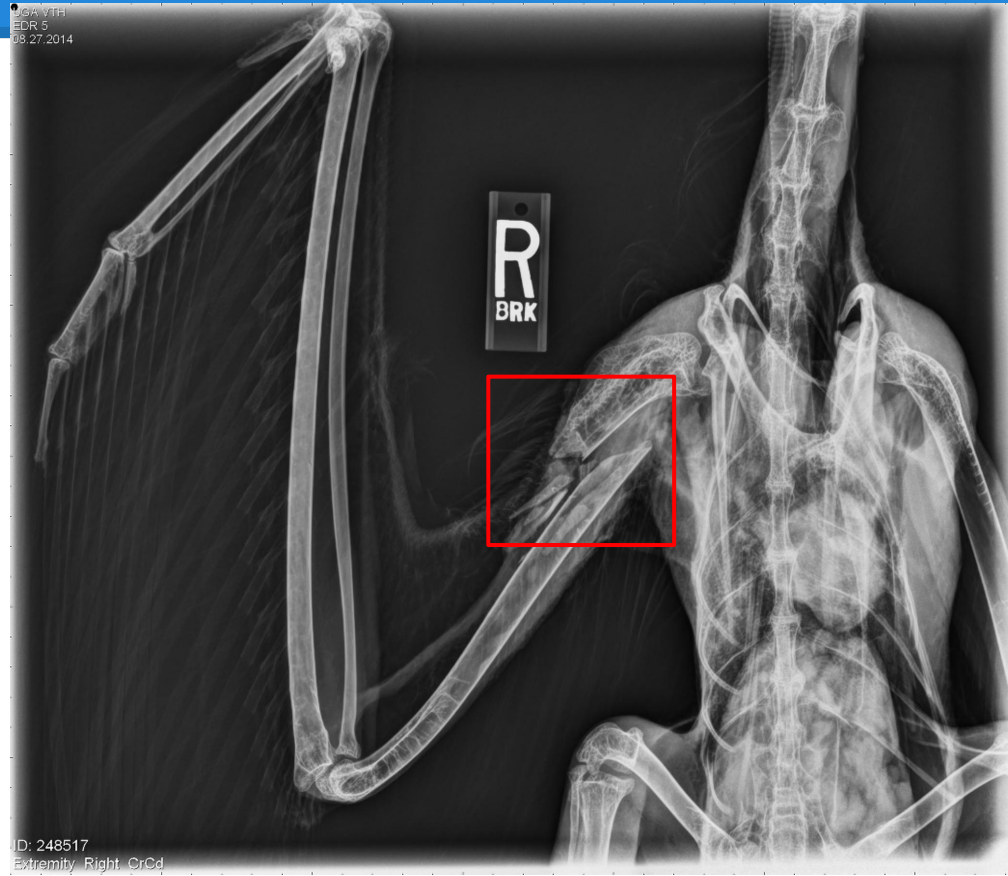
Bloody nares

Firm, round structure palpated below the keel



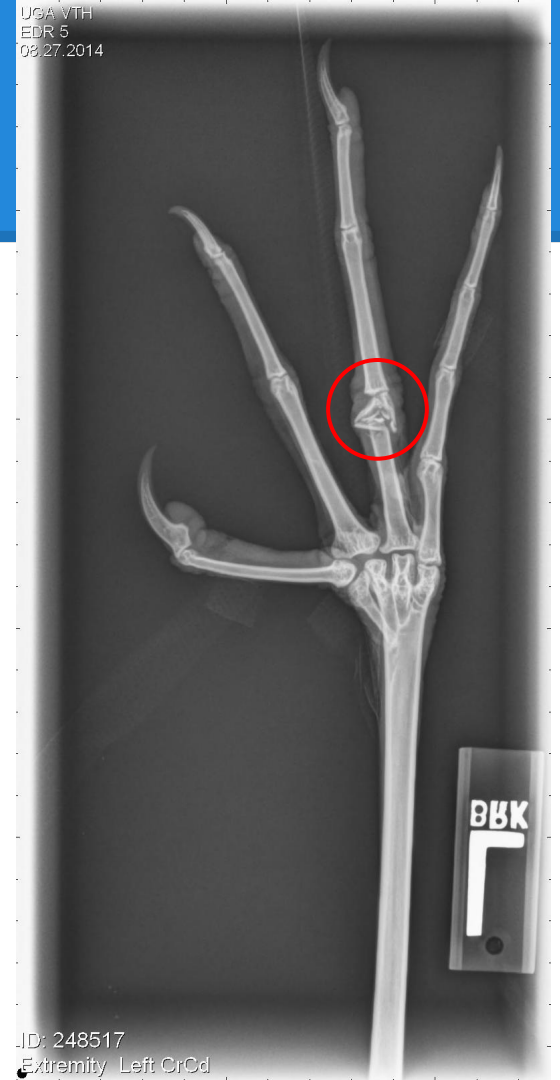Diagnostics

Radiograph results:
Fracture on the
right humerus



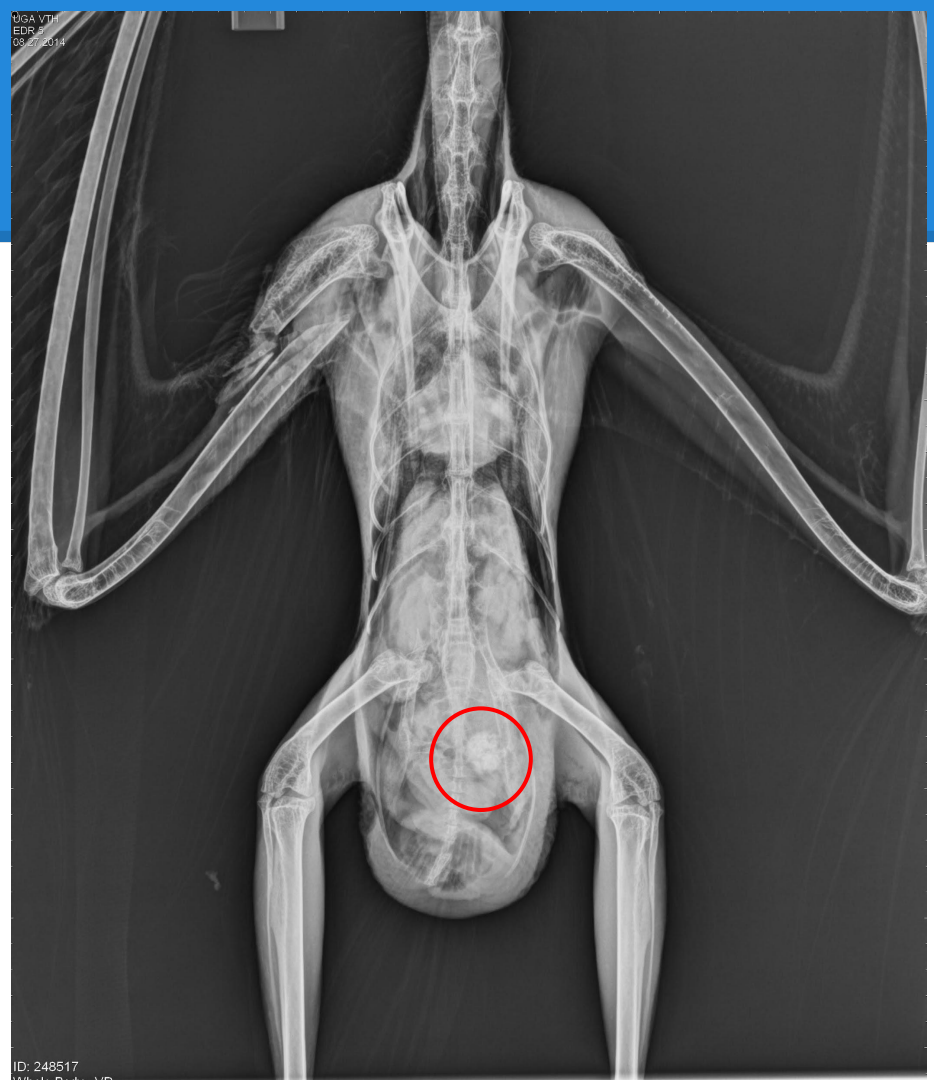Diagnostics

Radiograph results:
Left toe fracture



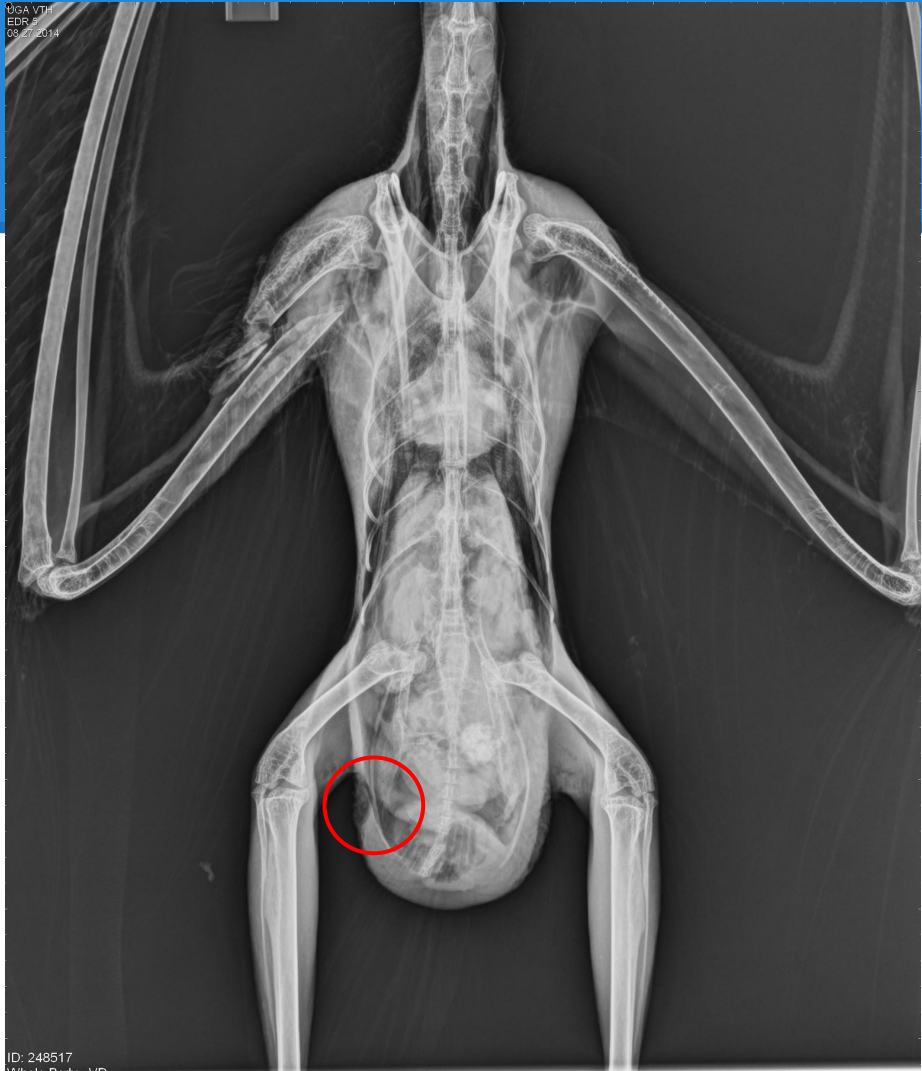Diagnostics

Radiograph results:
Soft tissue mass in
abdominal cavity



UGA VTH
EDR 5
08/27/2014

ID: 248517



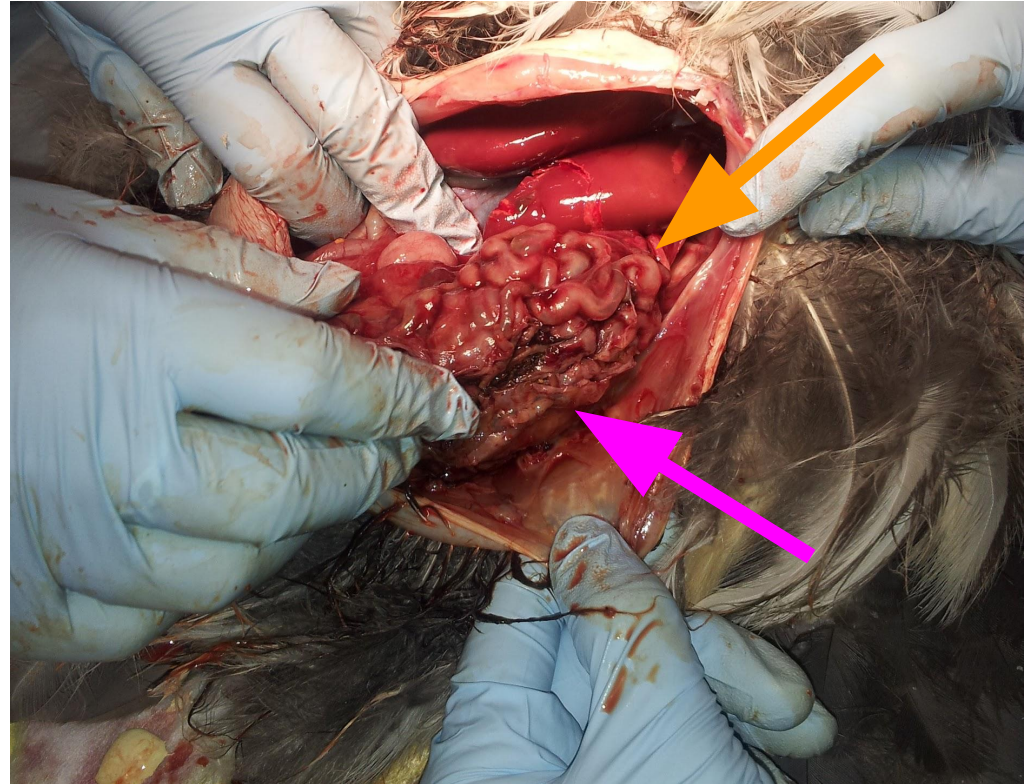
Outcome

Multiple fractures, poor quality of life
Euthanasia

Necropsy

Clumped small intestines
and stomach (attached to
the wall)

Small ovarian follicles





GREAT BLUE HERON
COPYRIGHT BIRDORABLE.COM

Questions?