

Red-Tailed Hawk

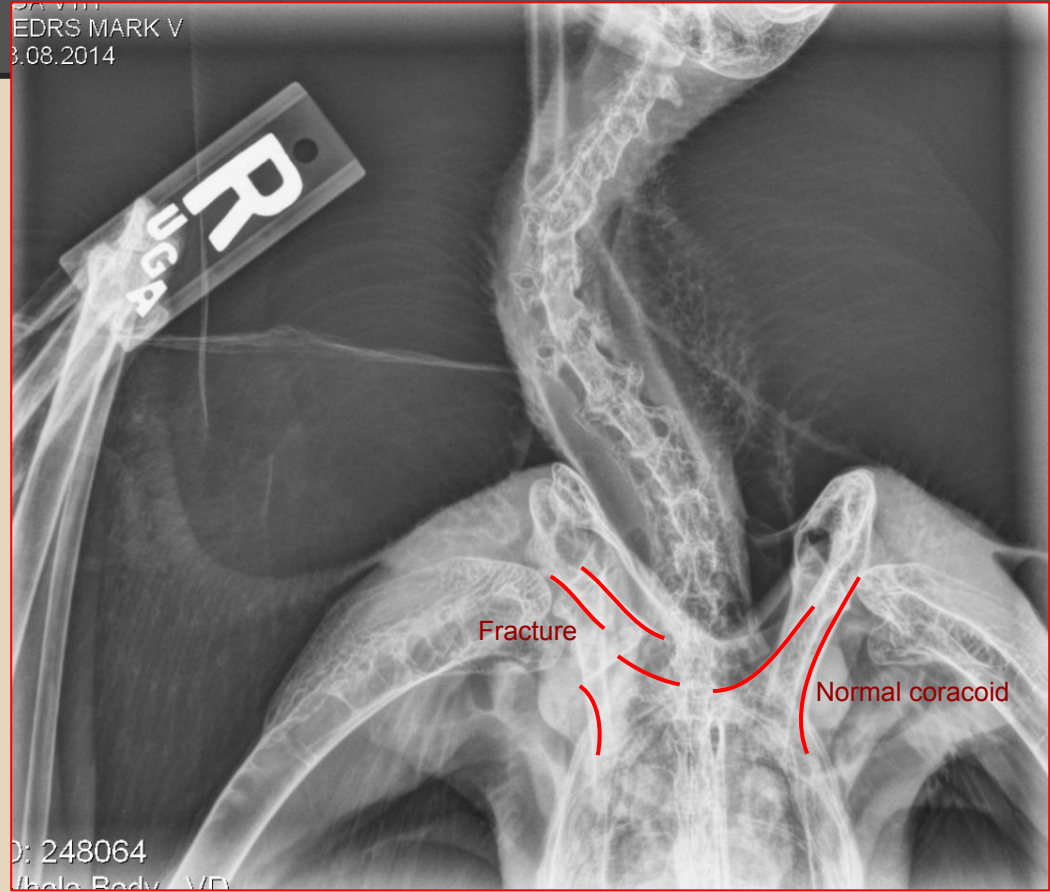
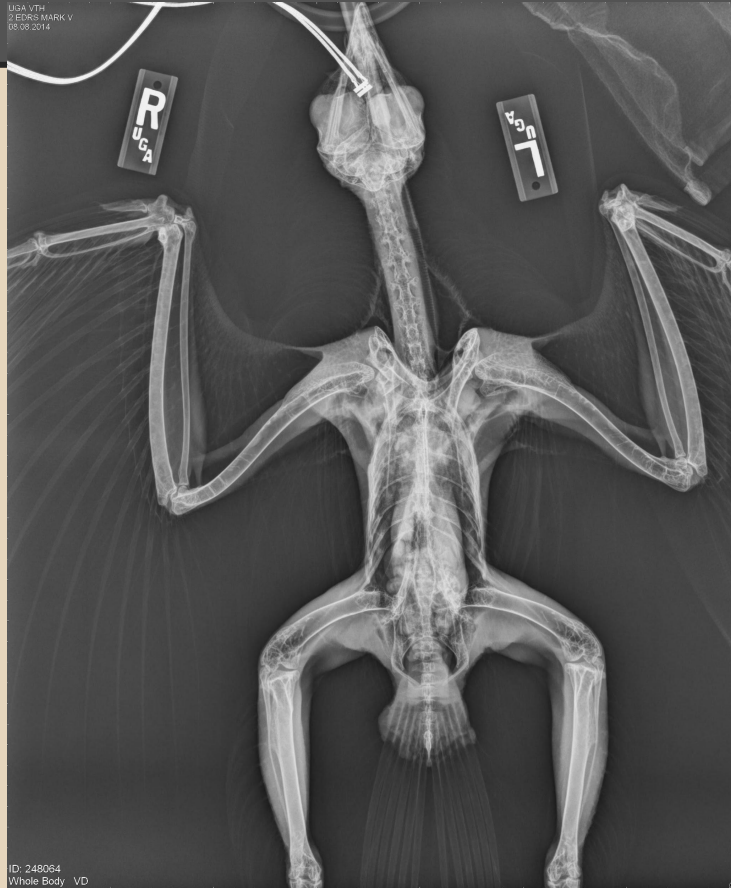Annemarieke de Vlaming
UVIS: 248064
WTC case #:14-208



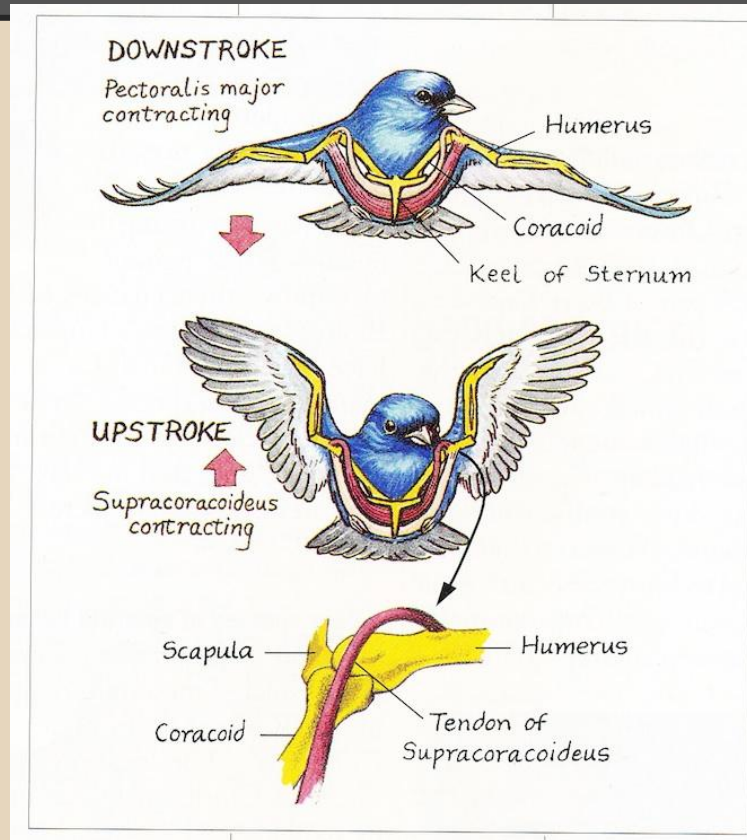
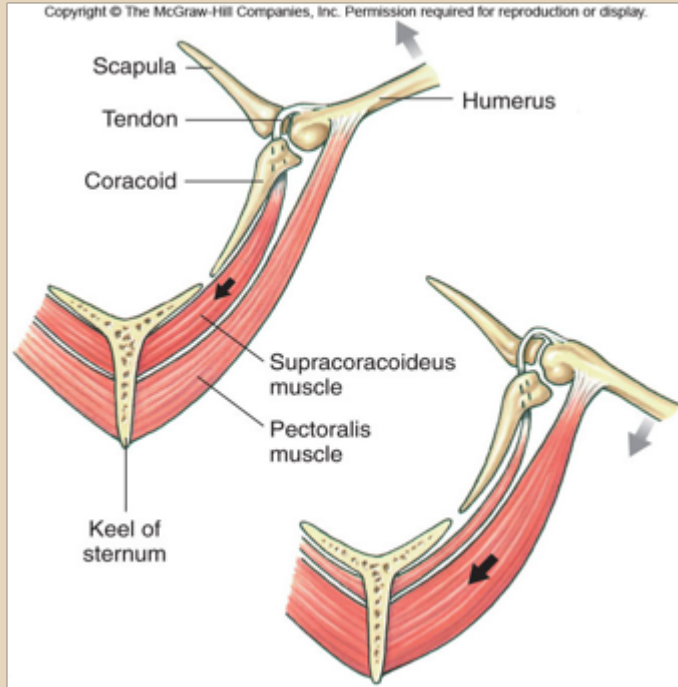
History & Physical Exam

- Found down in field
 - unable to fold wing properly
- Crepitus on pectoral girdle
 - injury to right wing

Radiology - coracoid fracture



Coracoid bone



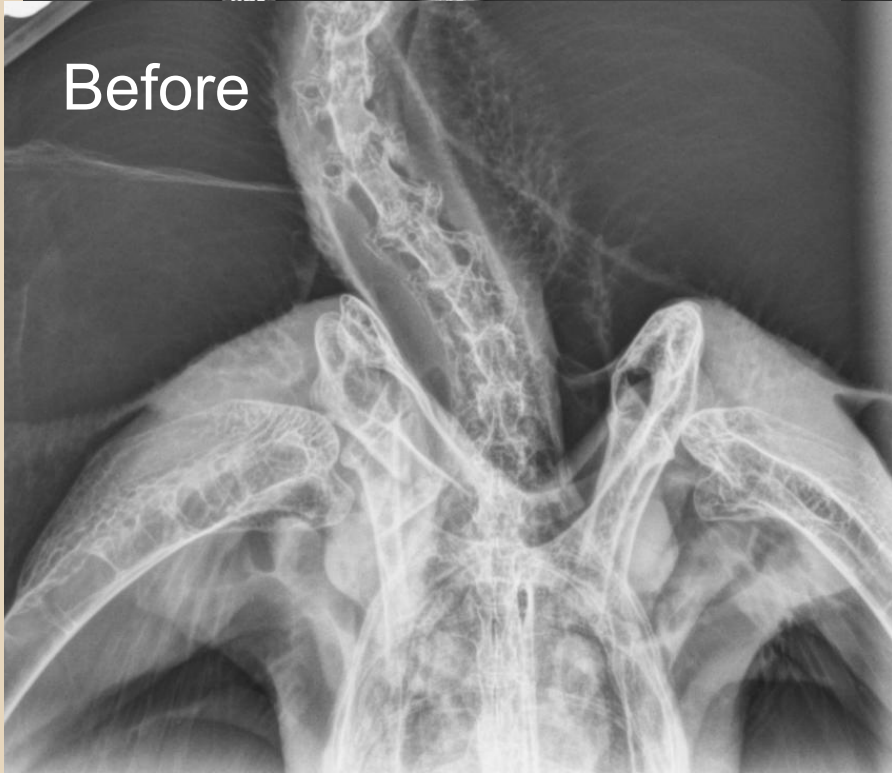
Plan & Treatment

- Difficult and small spot
 - no surgery
- Cage Rest
 - self-healing
 - callus
- Laser therapy
- Mouse diet - 3 BID

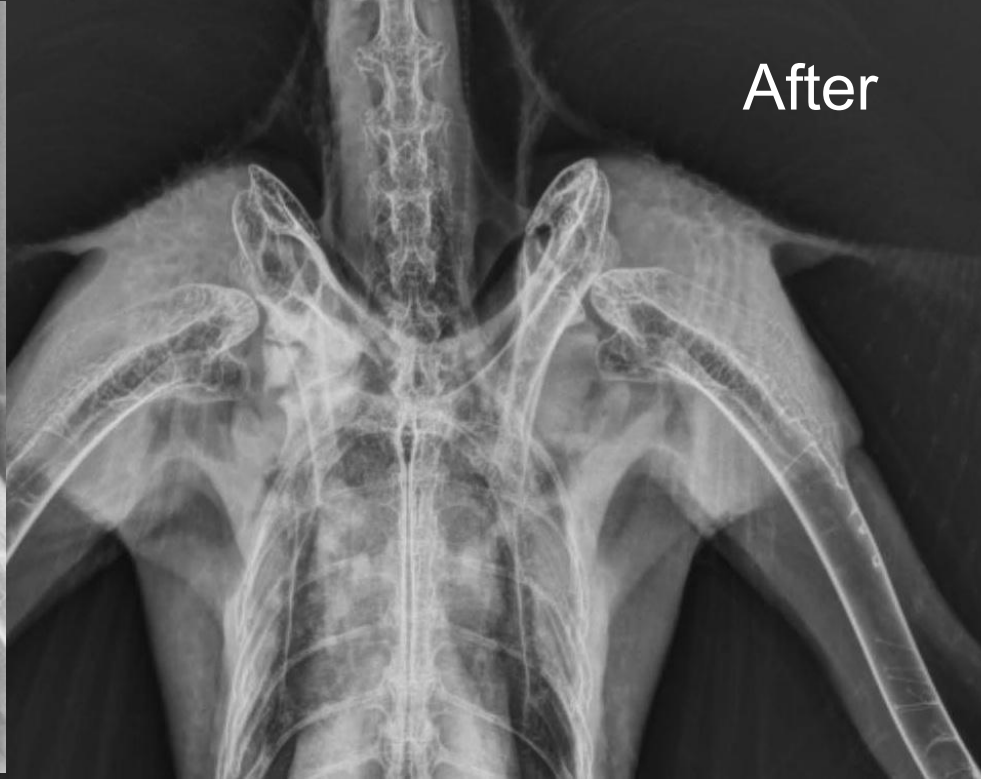Recheck Radiograph

U14
R

Before



After



Outcome

- Rehabilitation → AWARE
 - Follow up today = Ready for release!!
- Side notes:
 - Contact AWARE via e-mail - same day response
 - For transport to AWARE
 - Volunteer willing to drive on wednesdays